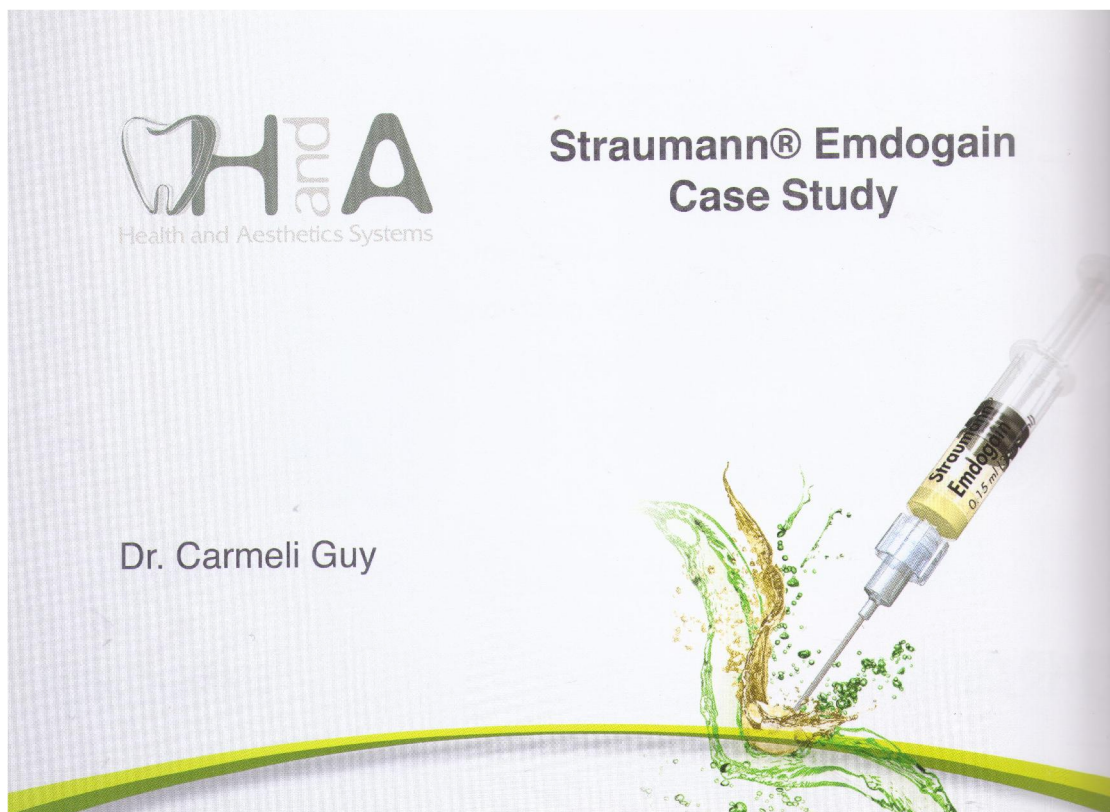
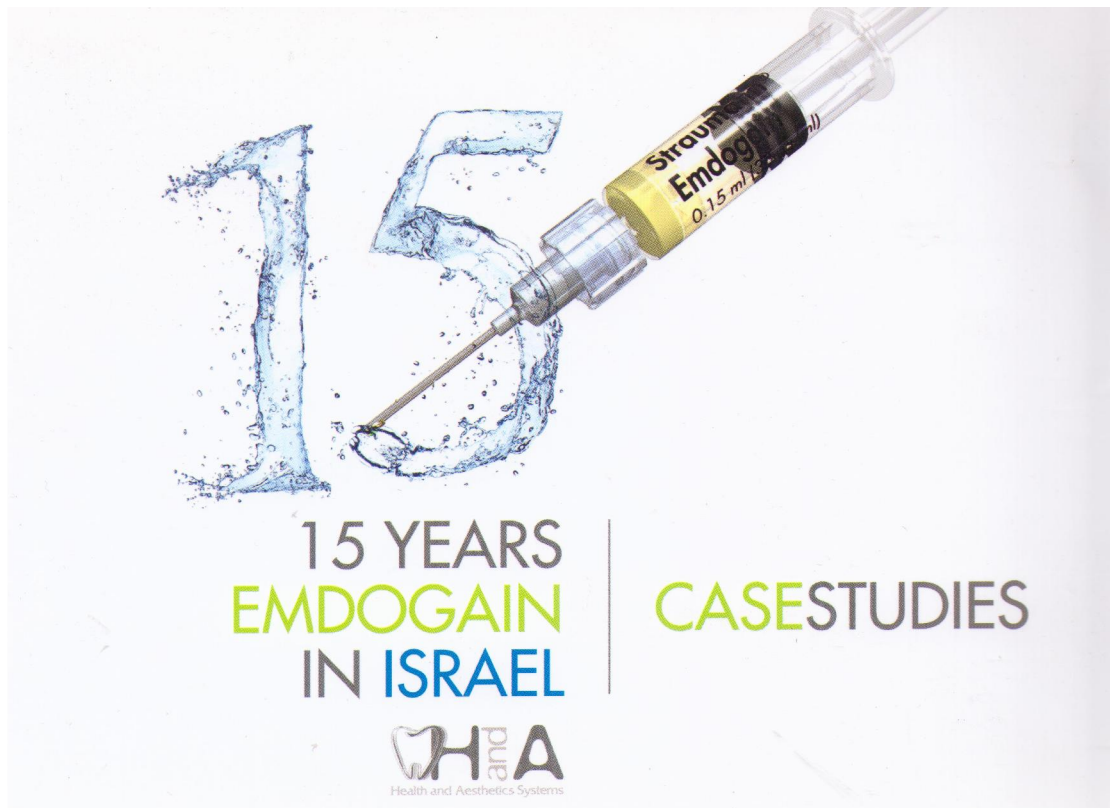
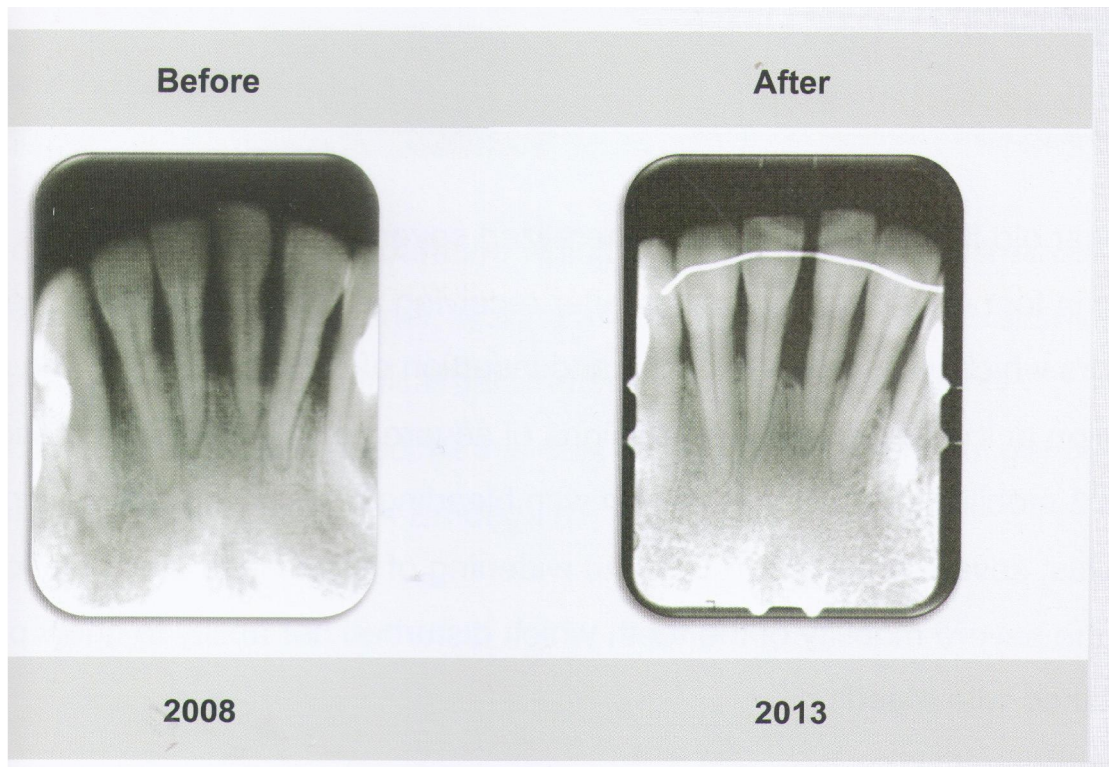
Patient	S.R.
Age	45
Sex	F
Relevant History	Generally healthy, light smoker
Complaint	Mobility of lower incisors, can't chew properly, bleeding

Clinical Description:

Lower incisors, class 3 mobility, probing up to 6 mm, bleeding on probing, GI 3, plaque, calculus, alveolar bone resorption, widening of PDL space.

Treatment:

Initial preparation: OH instructions, splinting (fixed lingual retainer), SRP.
After RE periodontal surgery including the use of EMDO.



Results and Conclusions:

45 year old female patient with generalized severe chronic periodontitis. She came in for periodontal evaluation after receiving a treatment plan for the lower incisors which included extractions and insertion of dental implants. The clinical situation at the beginning showed signs of severe periodontal inflammation – class 3 mobility, probing up to 6 mm with bleeding on probing, plaque and calculus, severe bone resorption and widening of PDL space. Her chief complaint was the severe mobility of the teeth which disturbed her ability to chew properly, combined with bleeding.

Results and Conclusions:

The patient underwent initial preparation which included oral hygiene instructions, splinting with a fixed lingual retainer, scaling and root planning. At reevaluation there was improvement in all clinical parameters, the patient was highly motivated. Oral hygiene was good. At this stage the patient underwent periodontal surgery which included the use of Emdogain.

Results and Conclusions:

After 5 years – the patient has no problem with chewing food, no signs of inflammation, probing up to 3 mm with no bleeding on probing. Radiographs show a stable situation with improvement of alveolar bone height at a few locations. The patient is following a strict maintenance program once every 3 months.